

Study Over 7000 Endosseous Implants Inserted during 25 Years in 3300 Interventions. Clinical Results in Different Anatomical and Functional Situations. Statistical Data and Over 20 Years Iconographic Documentation

This article was published in the following Scient Open Access Journal:

Journal of Dental and Oral Health

Received September 27, 2016; Accepted October 05, 2016; Published October 12, 2016

Luca Dal Carlo*

Calle dei Fabbri 924 (Sestiere San Marco), 30124 Venice, Italy

Abstract

Aim of work: Purpose of this work is to underline advantages of multi-modal implant approach, the goodness of whose choice is confirmed by the analysis of the data gathered during 25 years of implant practice, with gate controls at 5, 8 and 10 years. Suggestions useful to lead clinical practice are derived.

Materials and Methods: During 25 years (1989-2014) data concerning 7000 endosseous implants have been collected. Different implant shapes have been utilized, letting anatomical morphology lead the choice. An apparatus useful to rigidly join together implants with a titanium bar has been used to allow immediate load in cases of bony atrophy (intraoral welding machine). A proper database has been compiled.

Results: Overall success rates about any implant type here considered have been comprised between 95,5 and 99 % at five years gate control and between 87,7 and 96,6 % at 10 years gate control, widely overcoming the minimum requested by the most used success criteria [1,2]. Suitable implant shape, bicorticalism, immediate solidarization in atrophy cases, respect of healing biologic times, occlusal balance, periodic controls, are key factors for success.

Conclusions: Such a study, allows 1) getting some answers to frequently asked questions about treatment planning; 2) to conceive a schema to choose the correct implant shape in different clinical cases; 3) to help to reduce failure risks.

Different shapes of endosseous implant result useful to treat different anatomical morphologies. Choice about immediate or delayed loading follows anatomical and functional indications. Utilizing implant shapes which properly fit to wide or narrow bony ridges, success rates are similar. Different implant types can support the same fixed bridge. Connecting implants together by means of a welded bar results particularly useful in atrophy cases. Bicorticalism and respect of principles of static and dynamic occlusion are key factors for success. Passing of time leads to increase implant failures, demonstrating that 1-2 years gate control are not sufficient.

Keywords: Multi-modal implant dentistry, Statistical data over 7000 implants, Intra-oral welding, immediate load

Introduction

A 25 years study concerning 7000 implants of various shapes inserted during 3300 interventions in 1000 patients can be useful to understand which can be indications for implant planning and success expectations in the various anatomic areas of jaws in relation with prosthetic function.

Although some implant protocols are worldwide used to deal with edentulous anterior jaws, these standard treatments can resolve just a part of patient needs, imposing functional and prosthetic compromises. In many cases patient's anatomy leads to choose different implant techniques. In Italy, since the dawn of implant dentistry, besides the most common implant techniques, useful complementary implant techniques have been developed and checked about their success rate during the years. This study represents a data collection of different implant techniques, applied following anatomical and functional needs.

*Corresponding author: Dr. Luca Dal Carlo, Calle dei Fabbri 924 (Sestiere San Marco), 30124 Venice, Italy, Tel: +39 0415227465 Fax: +39 0412417637, Email: lucadalcarlo@yahoo.it

This statistic study is characteristic of the private professional way of working. All the patients have been followed by the same dentist during every step of the therapy, beginning from the first visit, passing through the operative sessions (surgical and nonsurgical), carrying on with periodic controls.

If patient is rich of bone, implants of any shape get good success expectations, which can be completely different when bone is scarce. Some implants shapes, which don't fit to ideal anatomic conditions, seem to be the best choice when bone width or depth is scarce.

Numerous studies show negative influence of occlusal unbalance on implant's prognosis, even after complete osseointegration [3-8]. Therefore, though some Authors [9-11] published studies whose conclusions are that it's possible to establish success prognosis of implants with a short follow up (1 or 2 years), I preferred to check implants at gate controls after 5, 8 and 10 years, getting the results here described, which confirm that implant failures increase following passing of time and that periodic controls are mandatory to prevent their occurrence and their consequences.

Materials and Methods

During 25 years (1989-2014) the data concerning implant interventions executed have been collected. A proper database has been compiled by registering:

- Surgical intervention progressive number
- Patient's progressive number
- Date of intervention
- Patient's gender
- Other interventions progressive numbers
- Patient's age
- Age's range (11-20, 21-30, 31-40, etc.)
- Patient's current and past pathologies
- Intervention's description

Five, eight and ten years after intervention's date the patients have been contacted, and when necessary visited, to check implants success. Data collected in the database have then been inserted in a Microsoft Excel file, including:

- Up-to-date date
- Implant's type
- Number of implants overcoming 5 years duration
- Number of implants failed before 5 years
- 5 years success percentage
- Number of implants overcoming 8 years duration
- Number of implants failed before 8 years
- 8 years success percentage
- Number of implants overcoming 10 years duration
- Number of implants failed before 10 years

- 10 years success percentage
- Deceased and nowhere-to-be-found patients

Deceased patients and nowhere-to-be-found patients have been excluded from this statistic.

Many implant systems have been used, whose selection has been depending on:

1. Anatomic characteristics gathered observing diagnostic tests and the objective examination done at the beginning of surgical intervention;
2. Prosthetic function;
3. Standard or urgency situation;
4. Immediate or delayed load.

All interventions have been done under local anesthesia, giving to the patients, if there weren't contraindications:

1. some anti-anxiety drops (benzodiazepines) to:
 - a. prevent troubles tied to anxiety,
 - b. counterbalance stress influence over tissues acidity,
2. an anti haemorrhagic pill (tranexamic acid) to reduce bleeding during intervention.

With rare exceptions, interventions in healed ridges have been done beginning by opening flaps, to carefully examine the bony ridge, to correctly manage the soft tissues and to activate all the biologic post-surgical inflammation processes which lead to new bone regeneration and optimum soft tissues healing.

Post-extractive implants have all been inserted in fresh extraction sites.

Except for about 20 overdentures, treated with the O-Rings technique, the definitive prosthesis has all been cemented.

During the years some implant systems have been abandoned, to get better performing shapes or simply because they are no more on sale, even if apart of them had good characteristics and success rates.

Many implant shapes have been utilized (Figure 1):

Submerged screw implants (2164 implants)

Ten implant systems have been utilized (most utilized: n. 5-9 in Figure 1). These implants have been employed both in long time healed bony ridges and as immediately post-extractive implants, normally with delayed load, but also with immediate load.

Non-submerged screw implants (212 implants)

Three implant systems have been utilized (most utilized: n. 10-11 in Figure 1). These implants have been employed both in long time healed bony ridges and as immediately post-extractive implants, just with delayed load.

One-piece screw implants (2495 implants)

Eight implant systems have been utilized (most utilized: n. 12-19 in Figure 1). These implants have been employed both in long time healed bony ridges and as immediately post-extractive implants, with immediate load, rarely with delayed load.

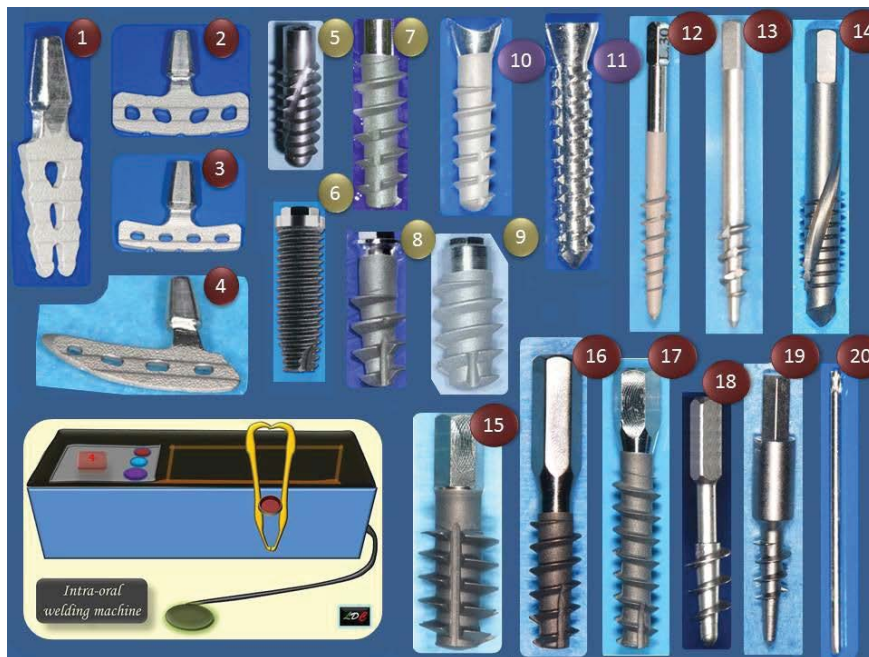


Figure 1: Various shapes of endosseous implants utilized (red: one-piece implants; brown: submerged implants; violet: non-submerged implants)

Blade implants (693 Implants)

Three implant systems have been utilized (most utilized shapes n. 1-4 in Figure 1). These implants have been employed just in long time healed bone ridges, both with delayed load and with immediate load.

Needle implants (1401 implants)

One implant system has been utilized (n. 20 in Figure 1). These implants have been employed both in long time healed bone ridges and as immediately post-extractive implants, with immediate load, rarely with delayed load.

In Table 1 you can see the indications to utilize the different implant shapes.

In many cases implants have been joined together by means of using a titanium wire or bar welded in mouth by means of the Mondani intra-oral welding machine [12] (Figure 1). The importance of joining implants together to improve success rates is today recognized by numerous Authors [5,13-16].

Results

Patients considered in this study have been classified in ranges of age. In Table 2 it's possible to see frequency of interventions related to ranges of age.

No difference in success rate has been noticed in relation to patient's different ages and sex, according with other Authors conclusions [17].

Let's analyze the single implants utilized, referring to numbering visible in Figure 1.

Submerged screw implants (utilized since 1989)

The whole number of submerged screw implants utilized is of

Implant shape	Healed ridges	Post Extractive	Delayed load	Immediate load
Subm. screws	X	X	X	X
Non-sub screws	X	X	X	
Onepiece screws	X	X	X	X
Blades	X		X	X
Needles	X	X	X	X

Table 1: Range of utilization of every implant type

Age	21-30	31-40	41-50	51-60	61-70	71-80	81-90	91-100
Prc	3%	8%	15.7%	27%	29.2%	15.3%	1.6%	0.05%

Table 2: Interventions: ranges of age (period 1989-2014)

2164. Due to the good clinical results, N.7-8 narrow neck implant system has been used more than other systems, both in healed ridges and as immediately post-extractive implant, since 1989. N. 7-8 submerged screws are manufactured by the same company which produced Muratori gimlet submerged screws (Figure 2), from which they were derived improving prosthetic connection, but maintaining endosseous shape. Since 1995, a minority of these submerged implants have been subjected to immediate load, too.

N.7-8 implants got 98.3% (1258/1279) five years success rate, 97.3% (1013/1041) eight years success rate, 96.6% (761/787) ten years success rate. These implants have been used both in normal and atrophic anatomic situations.

Since 1995, guessing that submerged implants induce the same bony response as one-piece ones do, submerged screw implants have also been used with immediate solidarization by means of bar welded in mouth to join healing abutments together (Figure 3). This is done to obtain a very good soft tissues outcome in just one intervention [18]. Healing abutments are screwed inside

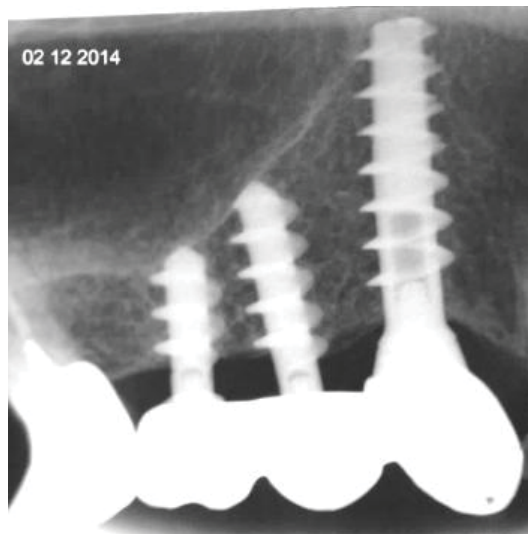


Figure 2: X-ray executed 24 years after insertion of 2 Muratori gimlet submerged screw implant in zones 1.5 and 1.6 (intervention Feb. 21, 1990) and 5 years after insertion of its evolution, N.8 screw implant, in zone 1.4 (intervention Apr. 02, 2009)

implants, in order to achieve immediate soft tissue repositioning around implant's profile and to allow immediate loading. After having performed the sutures, healing abutments are joined together by titanium bar or wire welded inside the mouth. This proceedings allow to maintain them in position and to protect implants from tongues pressure [19,20]. Immediate retention is removed after osseointegration and definitive prosthesis is built.

N. 5 implants, submerged version of N. 14 one-piece Mondani screw implants, were used both in healed ridges and as post-extractive implants since 1994. Particular characteristic of these

implants is a spiral groove which follows implant length. These implants got five years success rate of 94.3% (84/89), eight years success rate of 93.4% (57/61), ten years success rate of 92.8% (39/42).

N. 9 wide diameter screw implants have been used in fresh extraction sites since 1997. Overall success rate has been 98.3% (60/61). At 5 years (54/54) and 8 years (42/42) barrage success rate was 100%, at 10 years barrage success rate was 96.4% (27/28).

Twenty cases of severe mandibular atrophy have been treated since 1997 with a couple of N. 8 submerged screw implants and an overdenture, applied after 4 months, laying on the O-Rings technique. One screw implant was removed due to absence of osseointegration and substituted by means of a couple of needle implants welded together and modeled to provide overdenture anchorage. After definitive loading, no failure occurred during the period of time 1997-2007 (Figure 4).

Non-submerged screw implants (utilized since 1991)

The whole number of non-submerged screw implants utilized was 212 (18 N.10 and 194 N.11). N. 11 implants (Figure 1) are smooth surface non submerged implants. They had five years success rate of 95.5% (172/180), eight years success rate of 94.0% (141/150), ten years success rate of 87.7% (107/122). As the reader can see, it looks like failures increase after more than eight years. It's important to say that these implants have been used in many posterior depth atrophies. This fact, of course, does not facilitate long term implant duty. N. 10 Non-Submerged screws are rough surface wide threads screws, provided with an anatomic profile. Though this implant type till now didn't get failures, number of these implants inserted, just 18, is too little to gather significant statistical data.

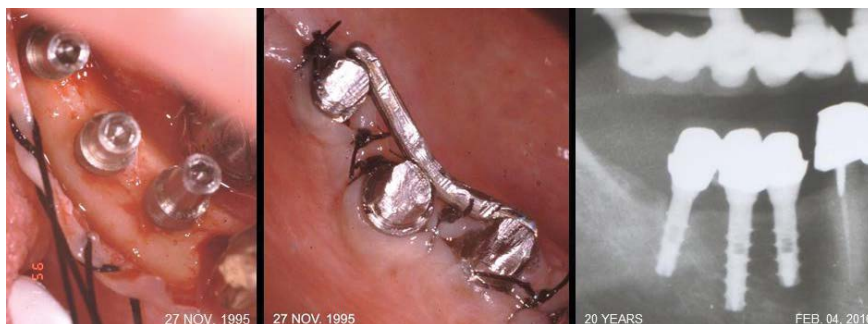

Figure 3: Nov. 27, 1995: three submerged N.4 screw implants were inserted in the 4.6-4.7 zone. Three specially made healing abutments were screwed into the three implants and a titanium bar was immediately welded in mouth to join implants together. At right: X-Ray taken 20 years later

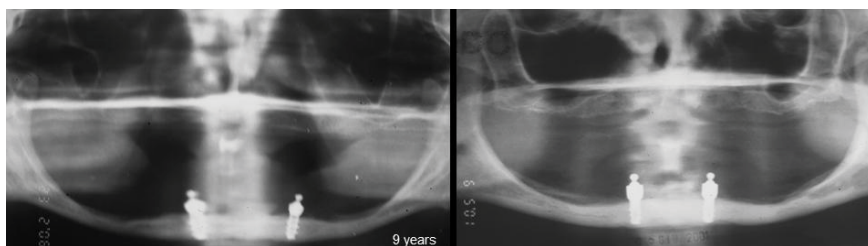

Figure 4: Couple of clinical cases of severe mandibular atrophy treated by means of overdenture on O-Rings

One-piece screw implants (utilized since 1990)

The whole number of one-piece screw implants utilized is 2495. These implants have been used in every anatomic situation, with immediate load, rarely with delayed load. Implant failures have often been resolved by replacing the screw implant with a wider one.

N. 13 one-piece implants (Garbaccio smooth surface grade 2 titanium screws) have been used in healed ridges and as immediately post-extractive implants in the anterior jaws. They got five years success rate of 97.4% (513/528), eight years success rate of 94.3% (298/316), ten years success rate of 94.0% (222/236).

N. 14 one-piece screw implants (Mondani type) have been used since 1991 especially as immediately post-extractive implants, in the interforaminal area and in the posterior superior areas. They got 93.2% (652/699) five years success rate, eight

years success rate of 90.4% (548/606), ten years success rate of 88.5% (465/525).

N. 12 one-piece implants (Garbaccio type rough surface titanium grade 4 screws), have been used as immediately post-extractive implants in the interforaminal area and in the posterior superior area, since 1999. Their overall success rate is of 97.7% (128/131).

N. 16-17 one-piece screw implants have been used in healed ridges and as immediately post-extractive implants in every zone of the mouth, with immediate load, since 1998 (Figure 5). After 5 years, their success rate was of 98.5% (195/198).

N.18 Tramonte one-piece screw implants have been used in healed ridges in the posterior inferior sector and as immediately post-extractive in the pre-maxilla, with immediate load, since 2000. They are also suitable for immediate substitution of failing screw implants. They got an overall success rate of 96.5% (111/115).

Data collected over 553 implants post-extractive of teeth and immediately loaded, collected during the period 1995-2005, showed a overall survival rate of 98.3%.

In some cases, since 1999, implants inserted soon after extraction of implants have been immediately loaded, with good results [21]. This has been possible by means of using wide diameter N. 15 and N.18 one-piece screw implants (Figure 6).

Blade implants (1989-2013 survey)

Blade implants have been utilized, following Linkow surgical protocol [22], to treat thin bone ridges both with delayed load and with immediate load. They've been used both in deep ridges and in atrophic ridges (Figure 7). Blades are built with thin neck bearing the abutment, following the principles of platform switching: finite element studies show low angular crestal bone loss around these types of necks [23]. 98.8% of the implants (427/432) passed the 5 years, 90% (299/332) 8 years and 88.1% (261/296) 10 years. These results look particularly good in consideration with the fact that many of the implants surveyed were inserted in atrophic posterior sectors, which is considered a risk factor for failure, because this condition is characterized by bad crown/root ratio and big chewing effort [24].

During 5 years (June 2000-June 2005), a study about immediate load applied on an one piece blade implant inserted in the posterior inferior sector (zone sixth-seventh) and an one-piece screw implant inserted in the fourth zone (mesial to mental foramen) was done. The two implants were connected in retention with a welded-in-

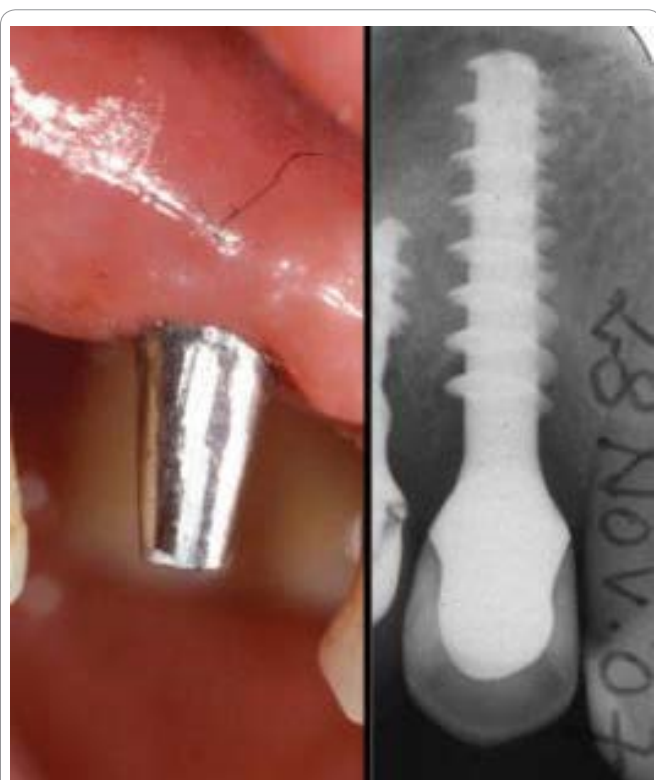

Figure 5: Abutment and 4 years X-Ray of N. 17 one-piece screw implant

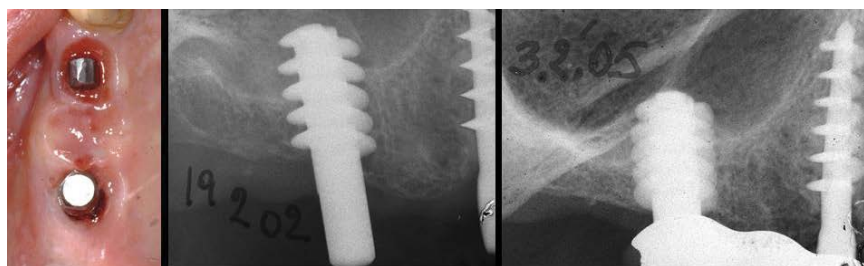


Figure 6: One-piece wide diameter screw implant (N.15) inserted immediately after extraction of implant in zone 1.6 and immediately loaded with adapted patient's bridge. At right, X-Ray taken after three years. Notice the bony tissue regenerated at implant apex and healthy conditions around the pre-existing screw implant in 1.4, previously inserted by a colleague

mouth titanium bar soon after insertion, by means of using the Mondani intra-oral welding machine (Figures 1 and 8). Twenty-seven semi-mandibles have been treated with 27 one-piece blades and 27 one-piece screws. In one case, the blade implant hurt under pressure with the provisional prosthesis and, for consequence, it's been stabilized by means of welding a bicortical needle implant to blade's abutment before fix prosthesis application. In two cases, the screw implant has been substituted by another, wider, screw implant, immediately loaded. Today's data about this study are then:

- 100% success rate with blade implants immediately loaded in the sixth-seventh zone, (one has been saved

by a needle implant). 96.2% (26/27) if we consider the hurting blade implant, then healed, as a failed one.

- 93.1% (27/29) success rate with one-piece screw implants immediately loaded in the fourth zone.

E.D.E. (Endosseous Distal Extension - 1993-2014 survey)

By EDE technique, whom first application dates back to June the 18th, 1993, it is possible to insert one part of the blade under untouched cortical bone and soft tissues in the posterior inferior area (Figure 9). These tissues don't therefore go subject to bone ridge reabsorption, which is never predictable.

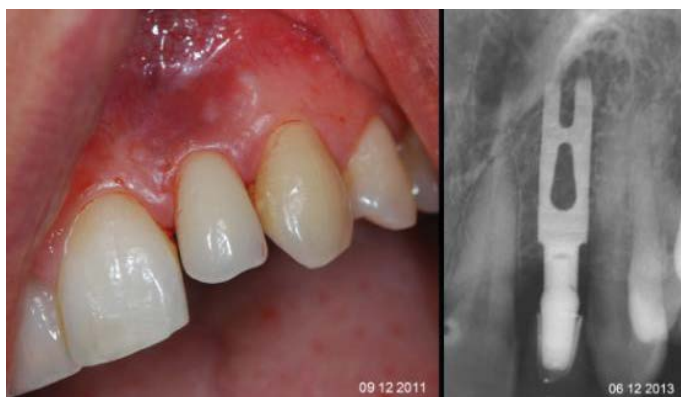

Figure 7: 18 years picture and 20 years X-Ray of blade implant inserted in zone 2.2 to a young woman (intervention April 19, 1993).

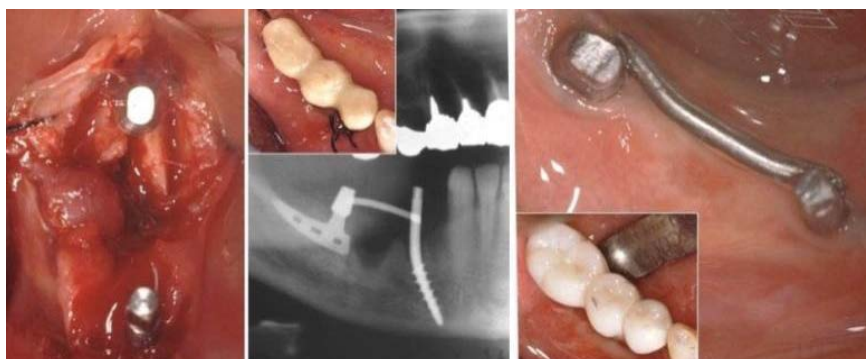


Figure 8: One-piece blade and bended one-piece screw inserted in zone 4.4-4.6, immediately welded and loaded. Soft tissue response after 3 months and definitive prosthesis

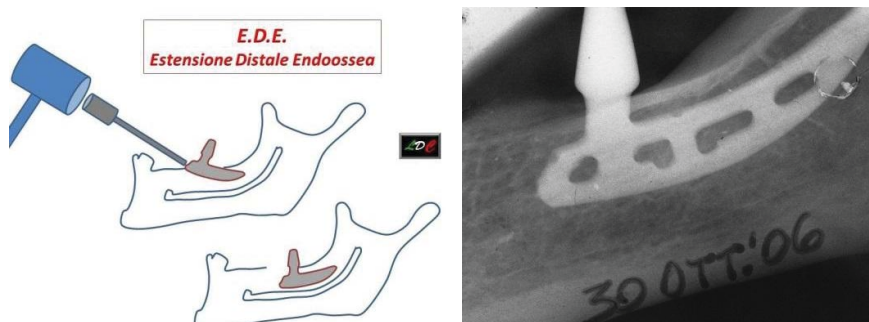


Figure 9: Scheme of the Endosseous Distal Extension Technique - X-ray of one clinical case

My first publications about EDE technique were written in Italian language [25] and Russian language [26]. During the period of time 1993-2014, 109 posterior ridges have been treated, 2/3 (73) were female, 1/3 (36) male patients. In 1998, asymmetric blades took place of the standard blades previously utilized. 90 ridges have been treated before 2010, more than 5 years before date of this publication. 87 of the 90 over 5 year's implants were trackable. Just 2 of the 87 implants were lost (97.7% 5 years success). 63 ridges were treated before 2005, more than 10 years before date of this publication. 50 of the 63 over 10 year's implants were trackable. 7 of the 50 implants were lost (86% 10 years success). If we separate the data about standard and asymmetric blades, we see that 10 years success with asymmetric blades was 93.3% (14/15). Asymmetric blades utilized since 2011 (under 5 years) have no failures. In fact, this shape allows to engage a long posterior part of the implant inside a solid housing, between the untouched superficial cortex and deep anatomical structures (mylohyoid line and inferior alveolar canal).

Needle implants

Needle implants have been always used in particularly difficult cases. Sometimes they have been used to treat post-extractive alveolus with immediate loading in the aesthetic area (Figure 10). Some other times they have been used to stabilize screw or blade implants before immediate load or dealing with severe atrophies of the posterior mandible.

As a matter of fact, the most precious application of needle implants is in working out distal atrophies with D3-D4 bone cases. Using a proper surgery, it's possible to pass along inferior alveolar nerve's side, reaching deep cortical bone, without sensitivity change problems and with immediate load (Figure 11). This technique is very safe and predictable.

The statistic results obtained by using this technique in posterior distal atrophic ridges with immediate loading are very good. 351 needle implants have been inserted, in 100 atrophic ridges, passing along nerve's side during the period of time 1996-2012 [27].

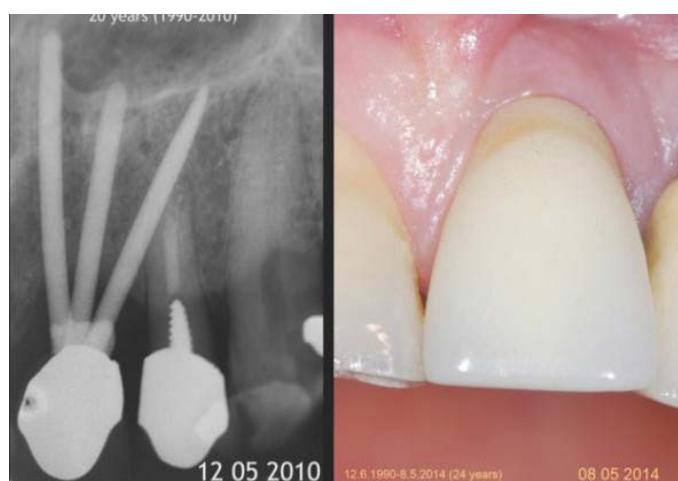

Figure 10: 20 years X-Ray and 24 years picture of a three welded-in-mouth needle implant inserted immediately after extraction of left central incisor (intervention June 12, 1990).

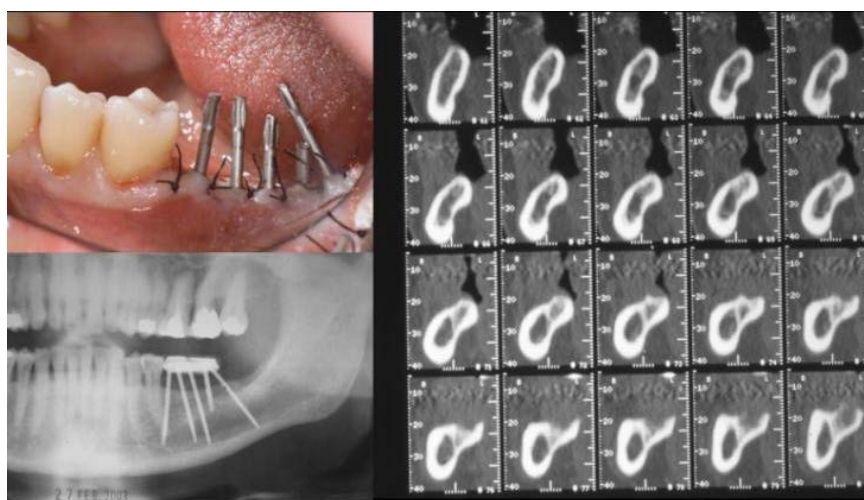


Figure 11: Posterior inferior left sector treated by means of 5 bicortical titanium needle implants, immediately welded in mouth and loaded

These implants have all been immediately welded together and immediately loaded. No patient had permanent lip anesthesia. Just 2.5% of the patients have had a temporary anesthesia (1-3 months). 97.5% of the patients have had no consequence from the intervention. 77 surgical interventions were performed. 5 years success rate was of 99% (296/299), 10 years success rate was 95.8% (138/144).

Discussion

Some success criteria described in international literature seem to be too simplistic, because they compare data about implant types which are suitable to easy clinical cases with data about implant types which are suitable just for difficult cases. Some implant shapes do not get brilliant success rates because they are used just in the difficult cases in which they are suitable, to which better and surer solutions do not exist. There's no point in abandoning these implant shapes, which are precious to deal with jaws severe atrophy.

All statistical data should be related to the difficulty of the anatomic situation in which implants have been used. You can expect that implant shapes which it's normal to utilize in wide, deep and dense bone ridges get better success rates than implant types which it's normal to utilize in thin, atrophic and empty ridges. When ideal anatomic conditions are selected to make clinical studies just to get brilliant success rates, you can only conclude that the implant system that has been utilized has brilliant success rates in ideal conditions, but which do not constitute a big percentage of the anatomic situations that every oral surgeon faces in his office.

Referring to distribution of load, according with studies with finite elements, thin implant neck and immediate stabilization by means of welded bar seem to allow remarkable reduction of peri-implant superficial reabsorption [23] (Figure 12).

It's very important to consider not only success rates of implants, but success of healing of oral disease, too.

Short report of statistical data is visible in Figure 13.

Referring to prosthetic solutions, we must distinguish the "overdenture", prosthesis totally or partially laying on soft tissues, from the prosthesis stably fixed to implants positioned in the entire bony arch which download the forces just inside the bone, providing teeth which are capable to restore chewing function similar to the natural one and, especially, to counterbalance the up-heaving force of the elevator muscles, restoring masticatory muscles and TMJ health.

Many extreme situations can be resolved in a brilliant and safe way by using a combination of implant techniques, which contribute all together to resolve patient's handicap, restoring physiologic functions.

Conclusion

A study of this type allows you to get some answers to frequently asked questions on implant dentistry and to design an operational scheme which will help in the selection of the implant in the different cases. Gathered data support the indication to use different implant shapes suitable for different anatomical situations, preferring a rough surface for the part

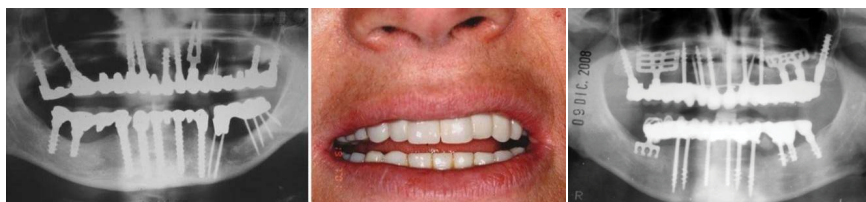

Figure 12: Full arch upper and lower fixed prosthesis on different shapes of endosseous dental implants

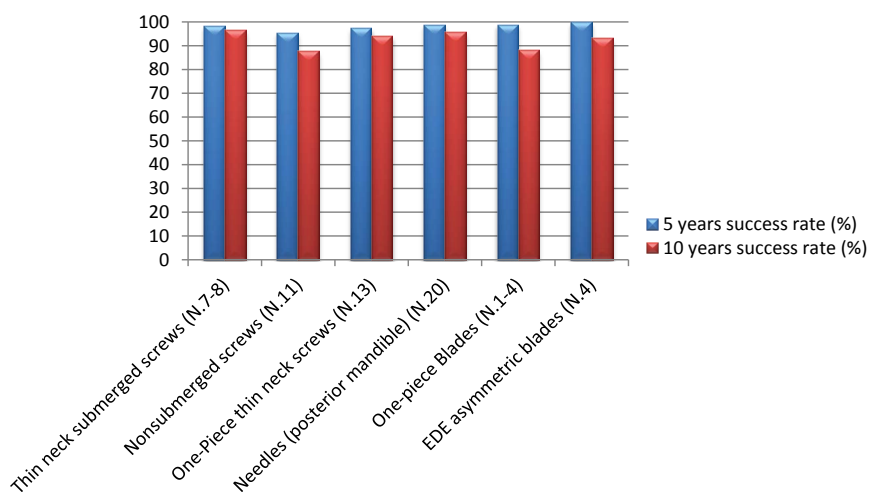


Figure 13: Success rate of most frequently utilized implants (Figure 1 for implant identification)

which is certainly destined to remain included in bone and smooth surface for the part contacting with the soft tissues and exposed in mouth. Success rate difference (1%) in favor of implants loaded after some months vs immediately loaded implants suggests the possibility of incongruous early load as one of the key factors to implant failures. This observation leads to suggest using immediate loading only when necessary. In these cases, when bony ridge allows correct axis of implant, one piece implant looks advantageous, due to better mechanical features, wide choice of gauges and absence of connection. The importance of bicorticalism is confirmed, both for better root / crown ratio and for stable support to the deep cortical, especially valuable for immediate load and conditions of D3-D4 bone. In the immediate post-extraction the lamina dura of the socket is a valid anchor point for implants. Implants are to be followed for many years, because the failures can occur at distance of years from osseointegration. In particular, it was noticed that the screw implants generally go more match to early problems, while blades go regularly to success at 5 years, but may undergo progressive failure between 8 and 10 years. Due to the fact that inferior jaw undergoes to elastic deformation under function, overall in the interforaminal area, in thin ridges thin and low grade titanium implants are suggested, having a modulus of elasticity close to bony one. One-piece grade 2 titanium implants can be bent during surgery to remedy defects of parallelism. This maneuver results particularly useful in the inter-foraminal area, where often implant inclination results lingual. Immediate post-extraction implants are to be performed after adequate surgical toilette of the socket. If they are stable, there is no contraindication to load them immediately. In the posterior inferior jaw, cases of osteoporosis may then be treated with proper thin cylindrical implants reaching the deep cortical bone carefully passing along inferior alveolar canal side. Surgical principles to insert screw implants are universal, with small variations depending on the shape. Immediate solidarization of implants with welded titanium bar is particularly useful for immediate loading, especially in cases of atrophy. Different implant types can support the same fixed bridge. It's always important to respect the principles of static and dynamic occlusion. In immediate loading, traumatic occlusion leads to premature failure. While it is generally preferable to avoid fixed prosthesis anchored to teeth and implants, this is possible for 3-4 units' bridges, with an implant as distal pillar. This results a better solution than forcing implant solutions in scarce bone to provide a prosthesis anchored just on implant pillars at any cost. Final prosthesis must be performed after stabilization of hard and soft tissues. A maximum number of 8-10 implants appear to be suitable for a full arch fixed prosthesis in healed ridge, to prevent horizontal bone loss due to excessive implants crowding. In the post-extraction, the experience of this study indicates that this problem does not exist, that anchoring to the lamina dura protects implants from perimplantitis and that function revitalizes the socket. 87% of all patients who have had the need to implant placement were aged between 40 and 80 years, 56% between 50 and 70 years.

References

- McKinney R, Koth DL, St DE, k DE. Clinical standards for dental implants. In: Clark JW, editor. Clinical Dentistry. Harperstown: Harper and Row. 1984;1-11.
- Albrektsson T, Zarb G, Worthington P, Eriksson AR. The long-term efficacy of currently used dental implants: A review and proposed criteria of success. *Int J Oral Maxillofac Implants*. 1986;1(1):11-25.
- Pasqualini U, Pasqualini ME. Treatise of Implant Dentistry - The Italian Tribute to Modern Implantology. 2009.
- Dal Carlo L, Rossi F, Pasqualini ME, et al. Intraoral welding and lingualized (lingual contact) occlusion: A case report. *Implants*. 2015;2:4-7..
- Rossi F, Pasqualini ME, Dal Carlo L, Shulman M, Nardone M, Winkler S. Immediate Loading of Maxillary One-Piece Screw Implants Utilizing Intraoral Welding: A Case Report. *J Oral Implantol*. 2015;41(4):473-475.
- Andrescu CF. Survival Rate of Immediately Loaded Implants Restored using the Intraoral Welding Technique: A Literature Review. *Dent Health Curr Res*. 2015;1:2.
- Meynardi F, Rossi F, Grivet Brancot L, Pasqualini ME. Not only bacteria but occlusal trauma cause of periodontal disease (Non solo batteri ma trauma occlusale all'origine della malattia parodontale). *Dental Tribune*. 2013.
- Rossi F, Pasqualini ME, Carinci F, et al. "One-piece" immediate-load post-extraction implants in labial bone deficient upper jaws. *Annals of Oral & Maxillofacial Surgery*. 2013;1(2):14.
- Canullo L, Sisti A. Early implant loading after vertical ridge augmentation (VRA) using e-PTFE titanium-reinforced membrane and nano-structured hydroxyapatite: 2-year prospective study. *Eur J Oral Implantol*. 2010;3(1):59-69.
- Vervaeke S, Collaert B, De Bruyn H. Immediate loading of implants in the maxilla: survival and bone loss after at least 2 years in function. *Int J Oral Maxillofac Implants*. 2013;28(1):216-221.
- Turkyilmaz I, Tumer C. Early versus late loading of unsplinted TiUnit surface implants supporting mandibular overdentures: a 2-year report from a prospective study. *J Oral Rehabil*. 2007;34(10):773-780.
- Mondani PL., Mondani PM. The Pierluigi Mondani intraoral electric solder. Principles of development and explanation of the solder using syncrystallization. *Rev Odontostomatol Implantoprotesi*. 1982;(4):28-32.
- Bergkvist G, Simonsson K, Rydberg K, Johansson F, Derand T. A finite element analysis of stress distribution in bone tissue surrounding uncoupled or splinted dental implants. *Clin Implant Dent Relat Res*. 2008;10(1):40-46.
- Matsuzaka K, Nakajima Y, Soejima Y, Kido H, Matsuura M, Inoue T. Effect on the amount of bone-implant contact when splinting immediate-loaded dental implants. *Implant Dent*. 2007;16(3):309-316.
- Grossmann Y, Finger IM, Block MS. Indications for splinting implant restorations. *J Oral Maxillofac Surg*. 2005;63(11):1642-1652.
- Behnaz E, Ramin M, Abbasi S, Pouya MA, Mahmood F. The effect of implant angulation and splinting on stress distribution in implant body and supporting bone: A finite element analysis. *Eur J Dent*. 2015;9(3):311-18.
- Schulte W, d'Hoedt B, Axmann D, Gomez G, Tuebingen. 15 anni di storia dell'impianto di Tuebingen e sua evoluzione con il sistema Frialit 2. *Quintessence International*. 1994:21-38.
- Dal Carlo L. Optimization of peri-implant marginal tissues in submerged implant dentistry. *Oralia Fixa*. 1998;10-13.
- Dal Carlo L. Influenza della Lingua sull'Integrazione degli Impianti Endosseii - Tongue's Influence on the Integration of Endosseous Implants. *Doctor OS Mag*. 2003;14(5): 479-484.
- Dal Carlo L, Brinon EN. Influencia de la lengua en la integracion de los implantes intra-oseos. *Revista Espanola Odontostomatologica de Implantes*. 2004;12:102-111.
- Dal Carlo L. Immediate load of implants immediately post-extractive of implants: the alveolar expanders. *Doctor OS*. 2007;18(4).
- Linkow LI, Mangini F. Tecniche Implantari ed Implantoprotesiche. *Piccin*. 1997;6:278.
- Lorenzon, G, et al. Biomechanical analysis of implant systems. *Dental Cadmos*. 2003;71(10):63-85.
- Noda K, Arakawa H, Kimura-Ono A, et al. A longitudinal retrospective study of the analysis of the risk factors of implant failure by the application of generalized estimating equations. *J Prosthodont Res*. 2015;59(3):178-184.
- Dal Carlo L. Nuova tecnica per l'inserzione di impianti a lama: Estensione Distale Endosseaa. *Dental Cadmos*. 2001;41-49.

26. Dal Carlo L. Endosseous Distal Extension: A new Technique that is useful to solve Clinical Cases characterized by scarceness of Cancellous Bone Tissue in the Lower Distal Sector. *Dental Cadmos*. 2001;16:41-49.

27. Dal Carlo L, Pasqualini ME, Carinci F, et al. A retrospective study on needle implants positioned in the posterior inferior sector: surgical procedure and recommendations. *Annals of Oral & Maxillofacial Surgery*. 2013;1(2):16.